



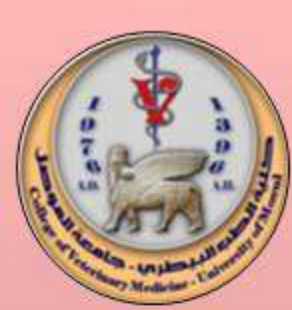College of Veterinary Medicine

Department of Anatomy



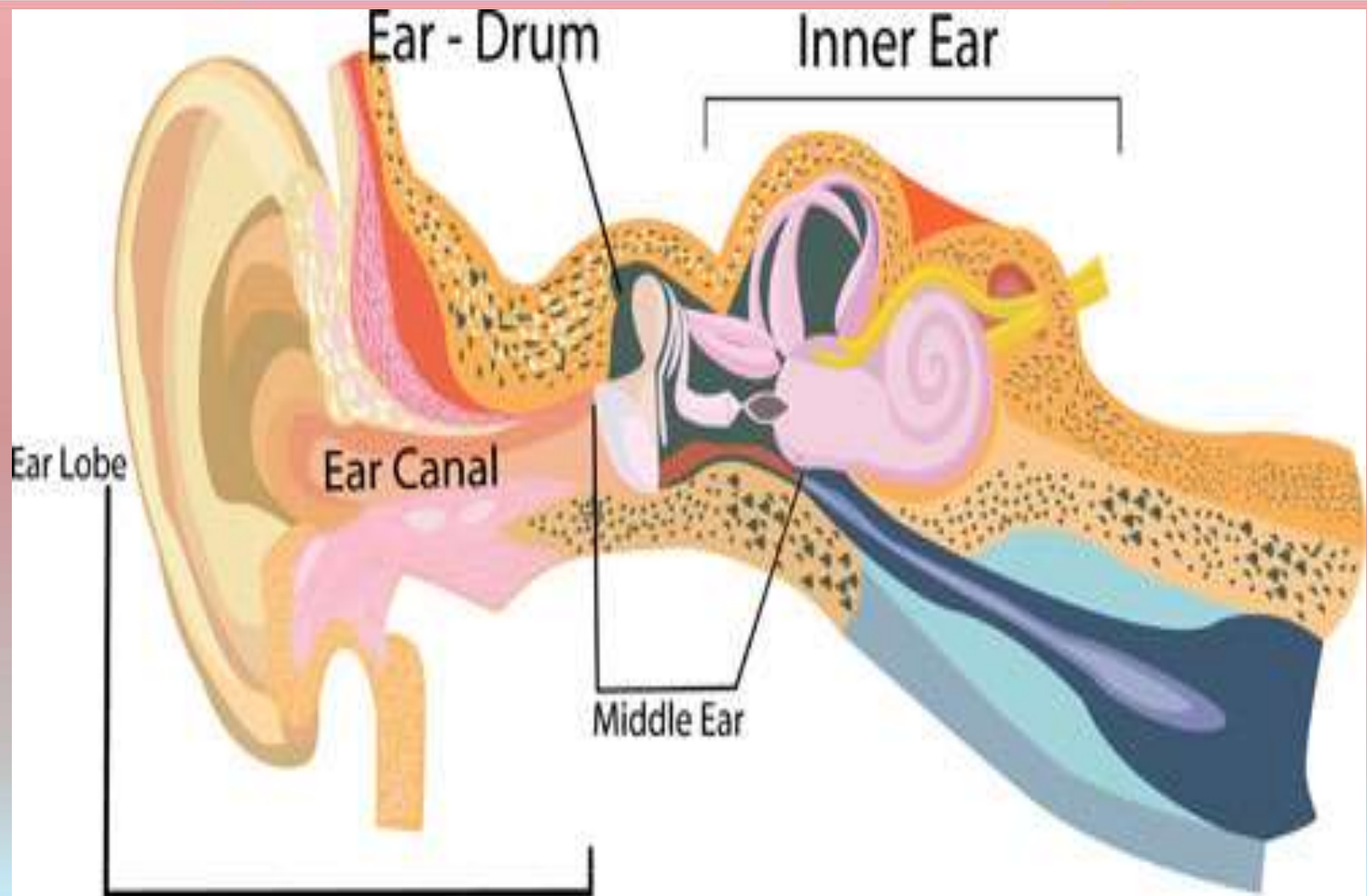
Ears

Dr. Qismah M. Salih



College of Veterinary Medicine

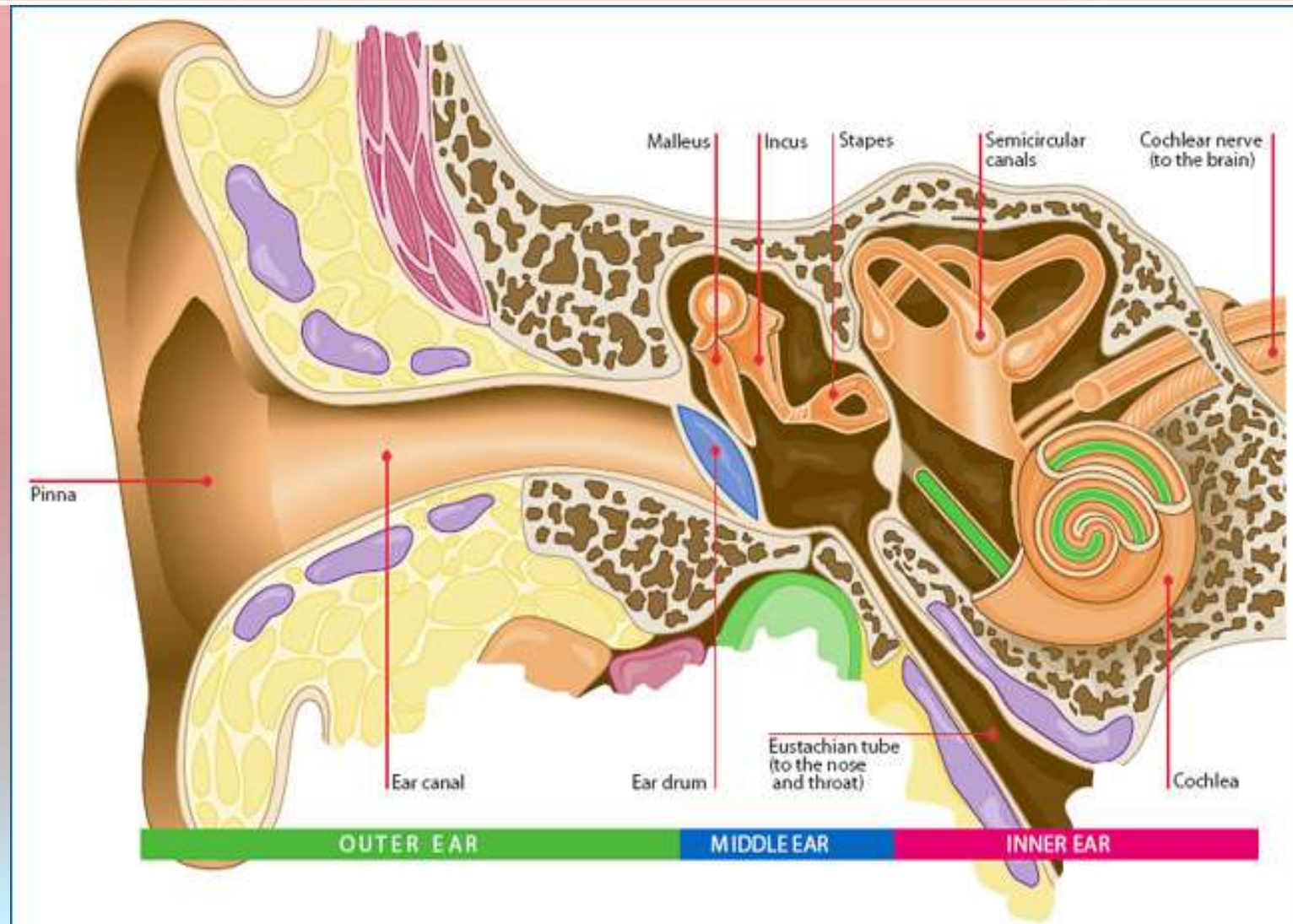
Department of Anatomy





College of Veterinary Medicine

Department of Anatomy



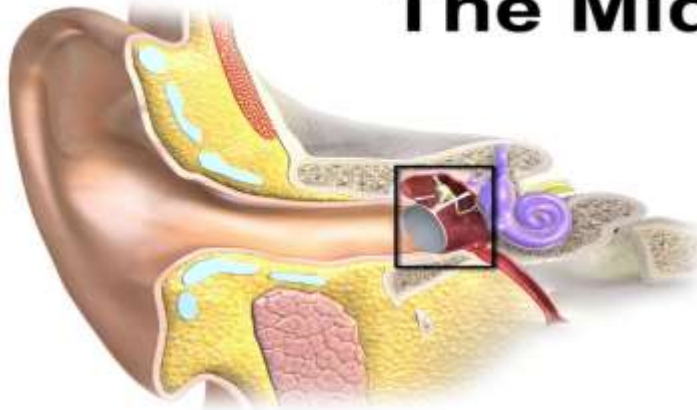

College of Veterinary Medicine

Department of Anatomy



The Middle Ear



Auditory ossicles

Malleus

Incus

Stapes

Stabilizing ligaments

External acoustic meatus

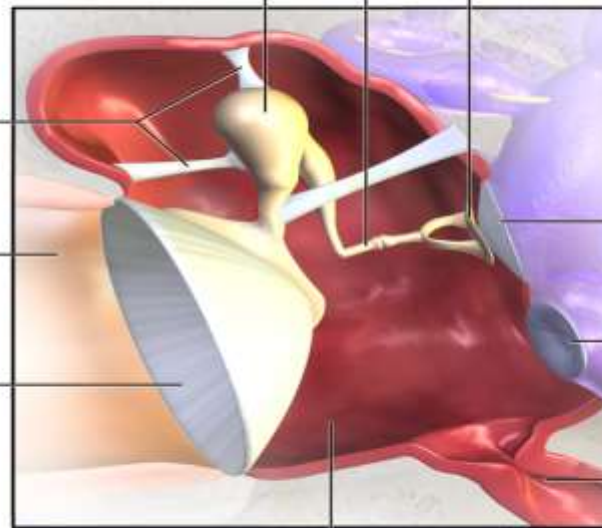
Tympanic membrane

Oval window

Round window

Auditory tube

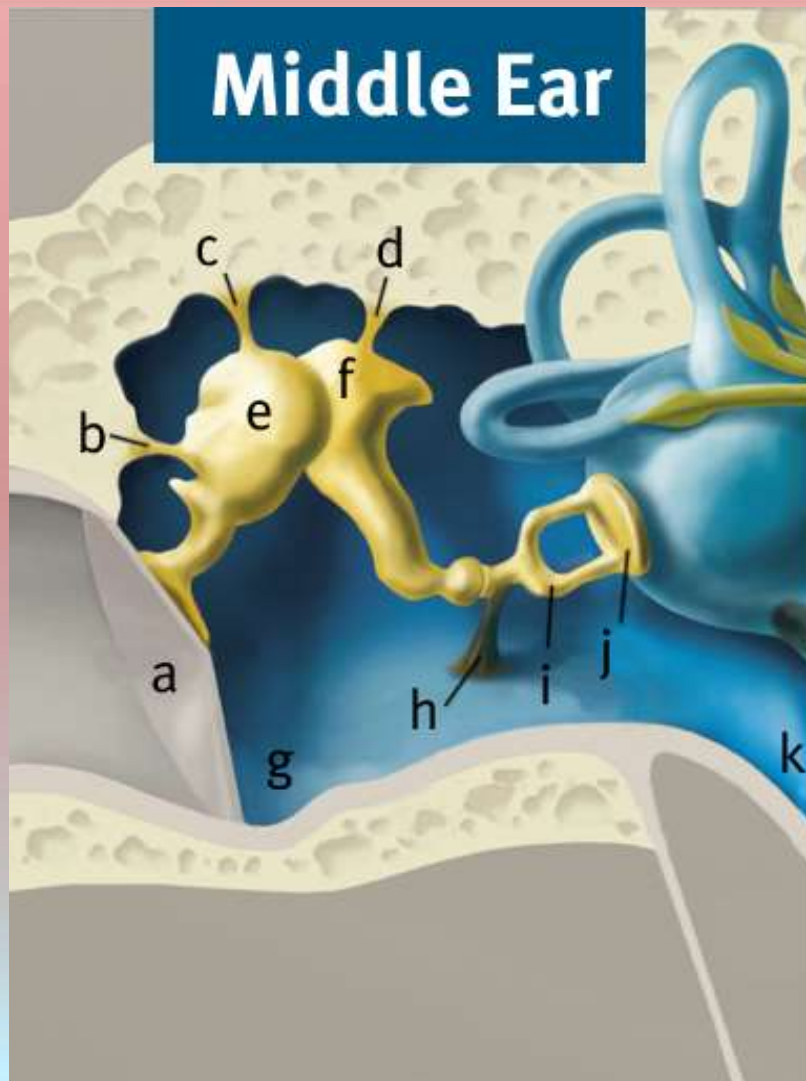
Tympanic cavity
(middle ear)





College of Veterinary Medicine

Department of Anatomy



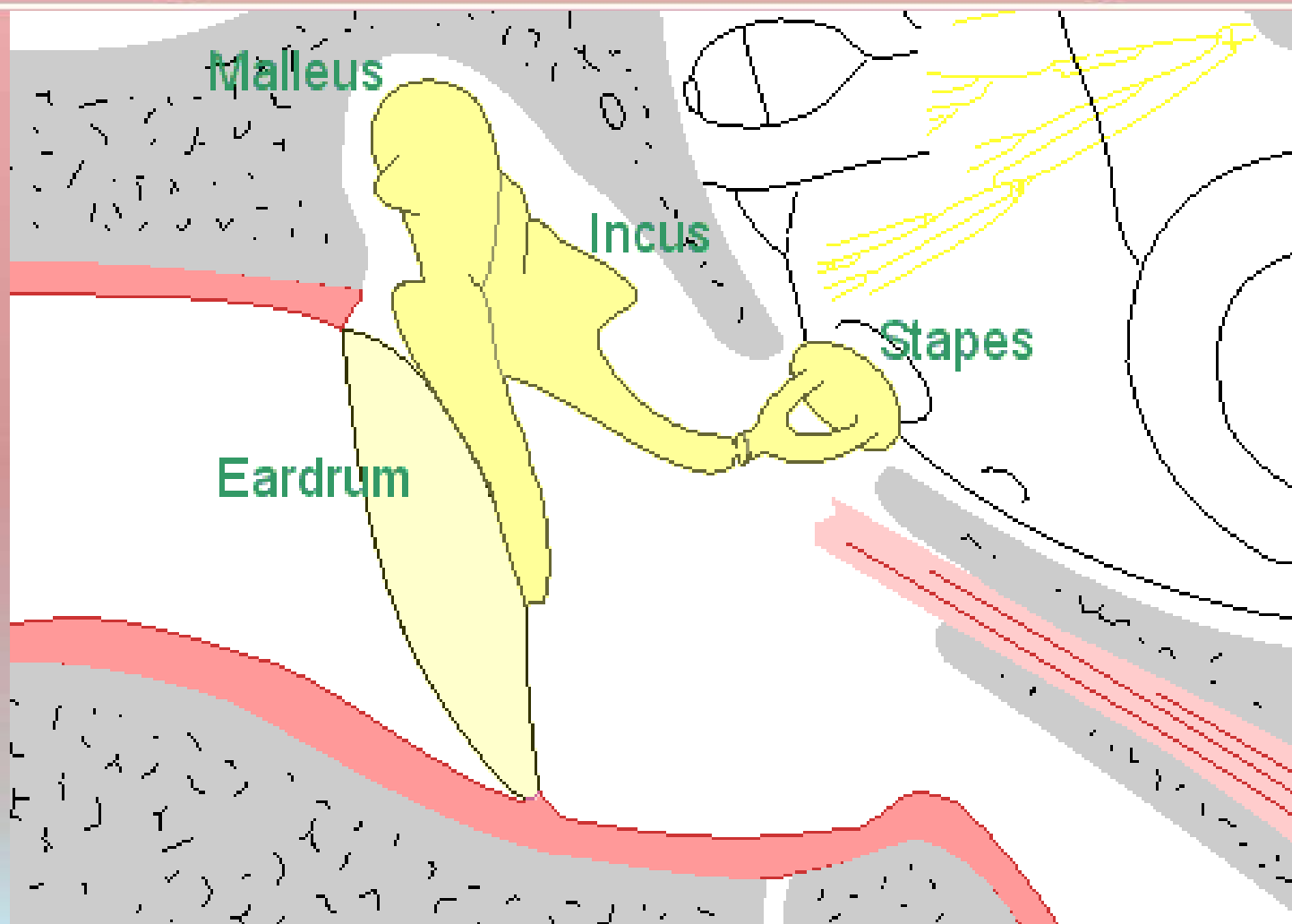
Middle Ear

- a) Eardrum
- b) Lateral malleolar ligament
- c) Upper malleolar ligament
- d) Incudal ligament
- e) Malleus
- f) Incus
- g) Middle ear
- h) Stapedius muscle
- i) Stapes
- j) Stapes footplate and oval window
- k) Eustachian tube



College of Veterinary Medicine

Department of Anatomy



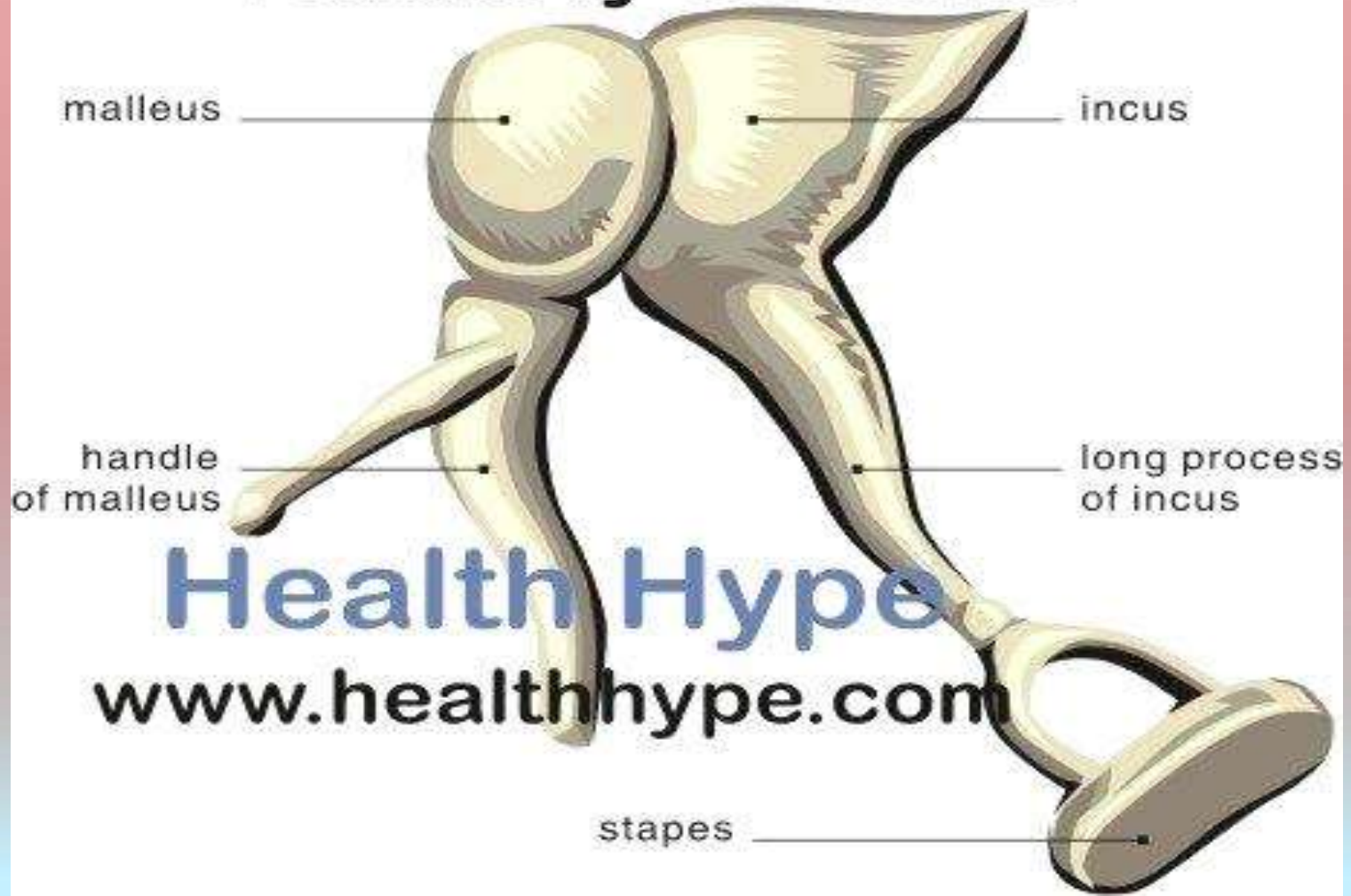


College of Veterinary Medicine

Department of Anatomy



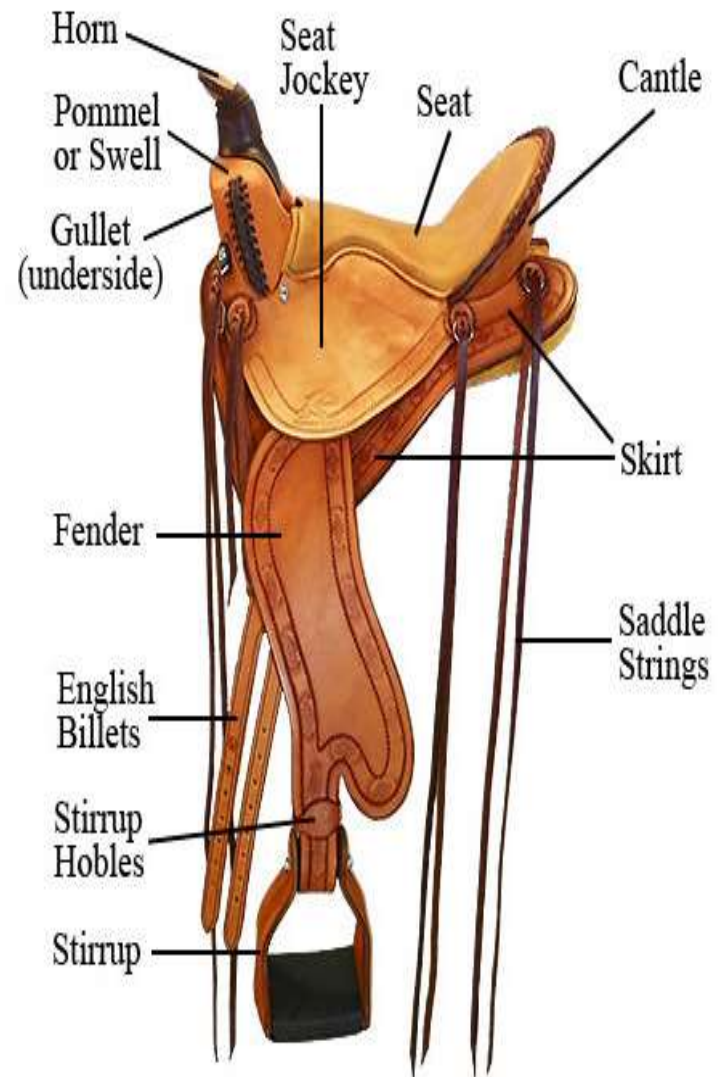
Auditory Ossicles





College of Veterinary Medicine

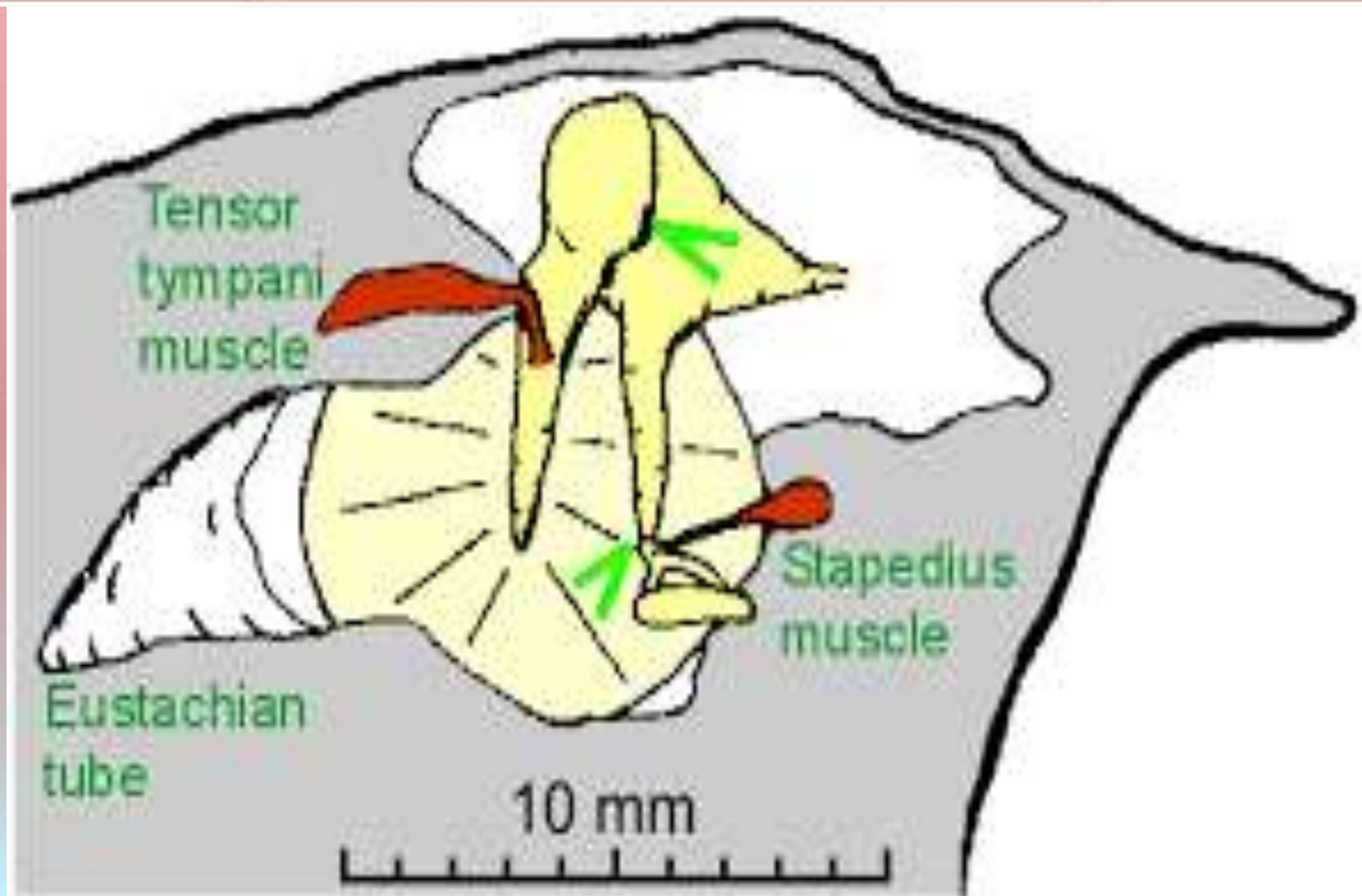
Department of Anatomy





College of Veterinary Medicine

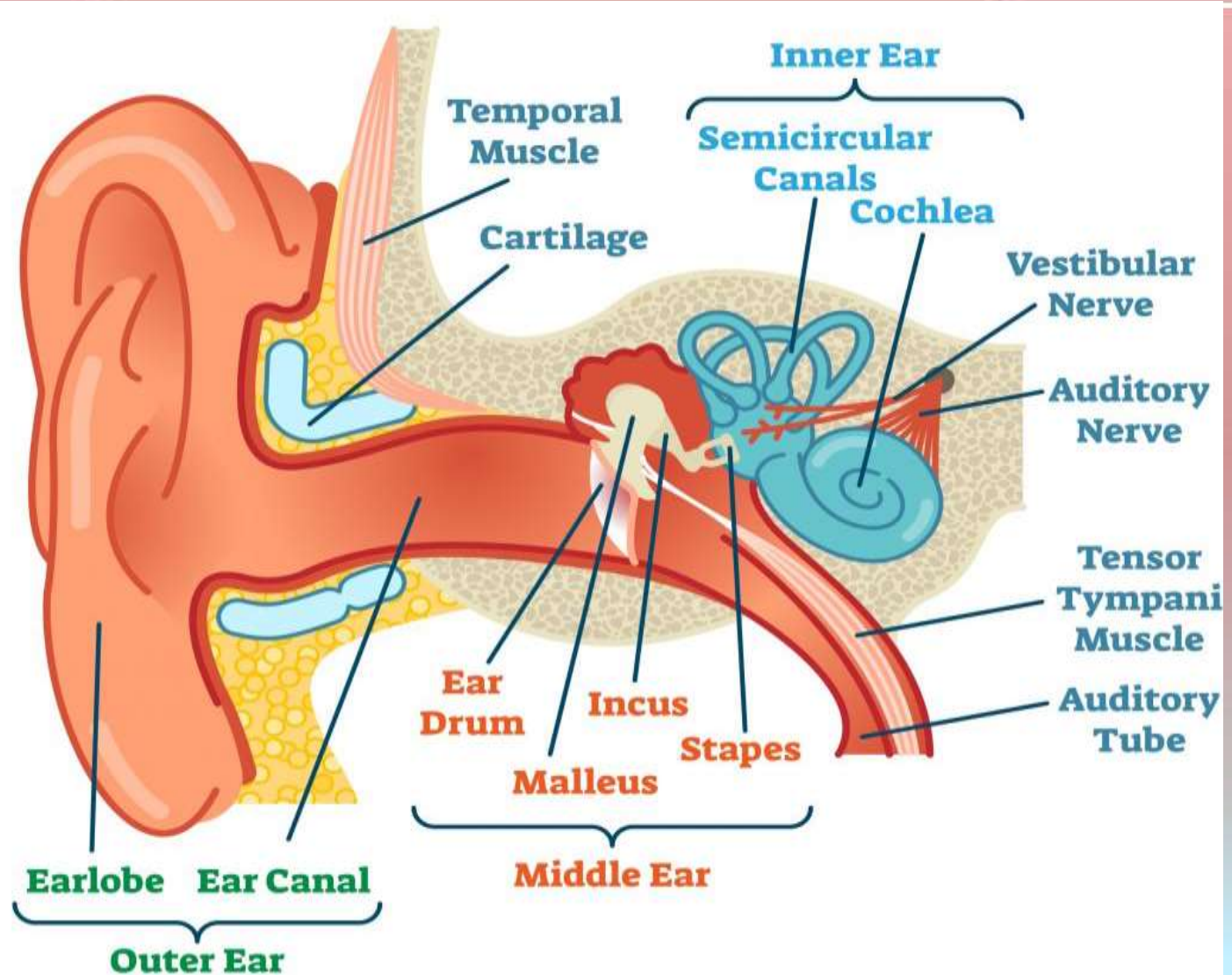
Department of Anatomy





College of Veterinary Medicine

Department of Anatomy





College of Veterinary Medicine

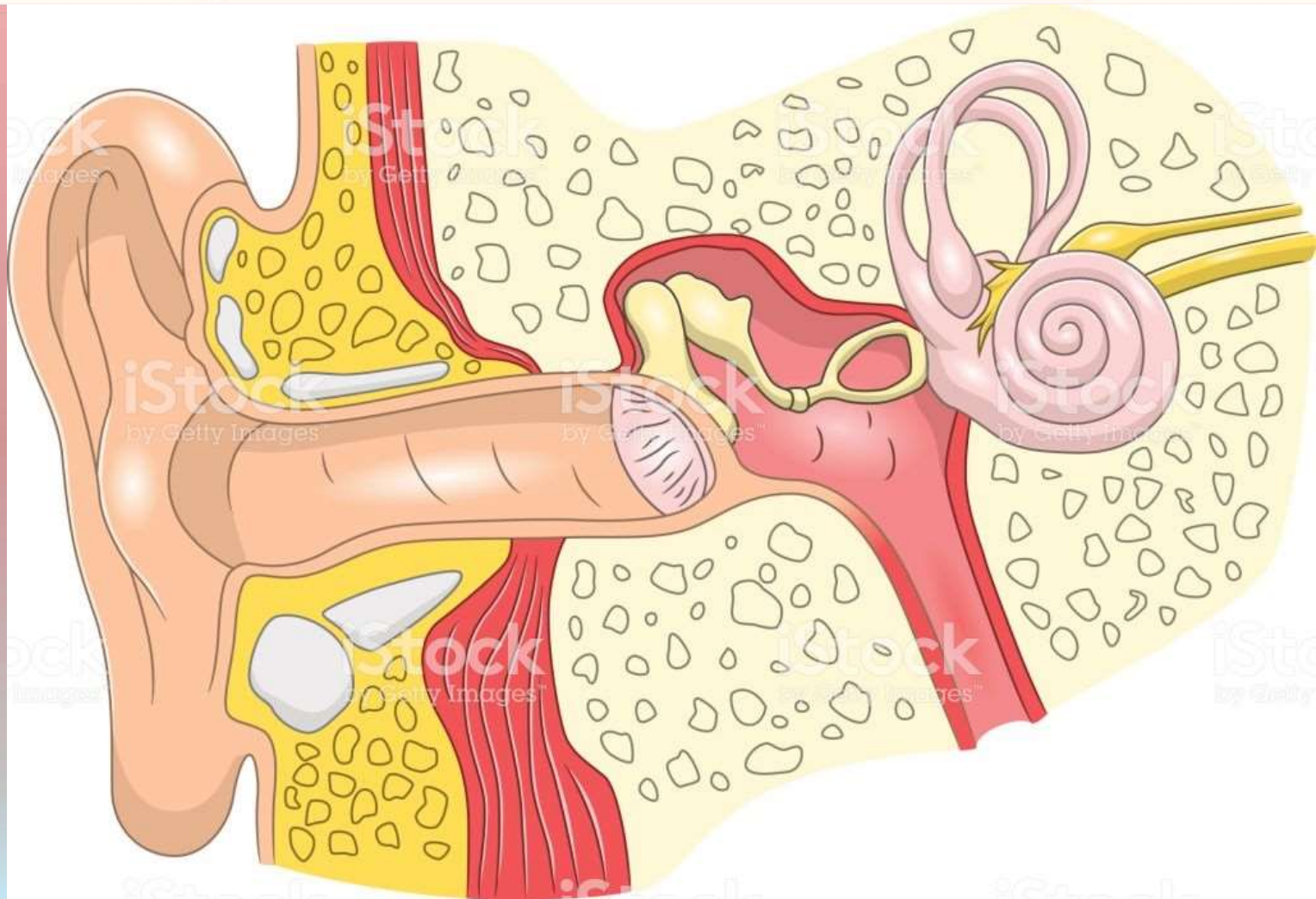
Department of Anatomy





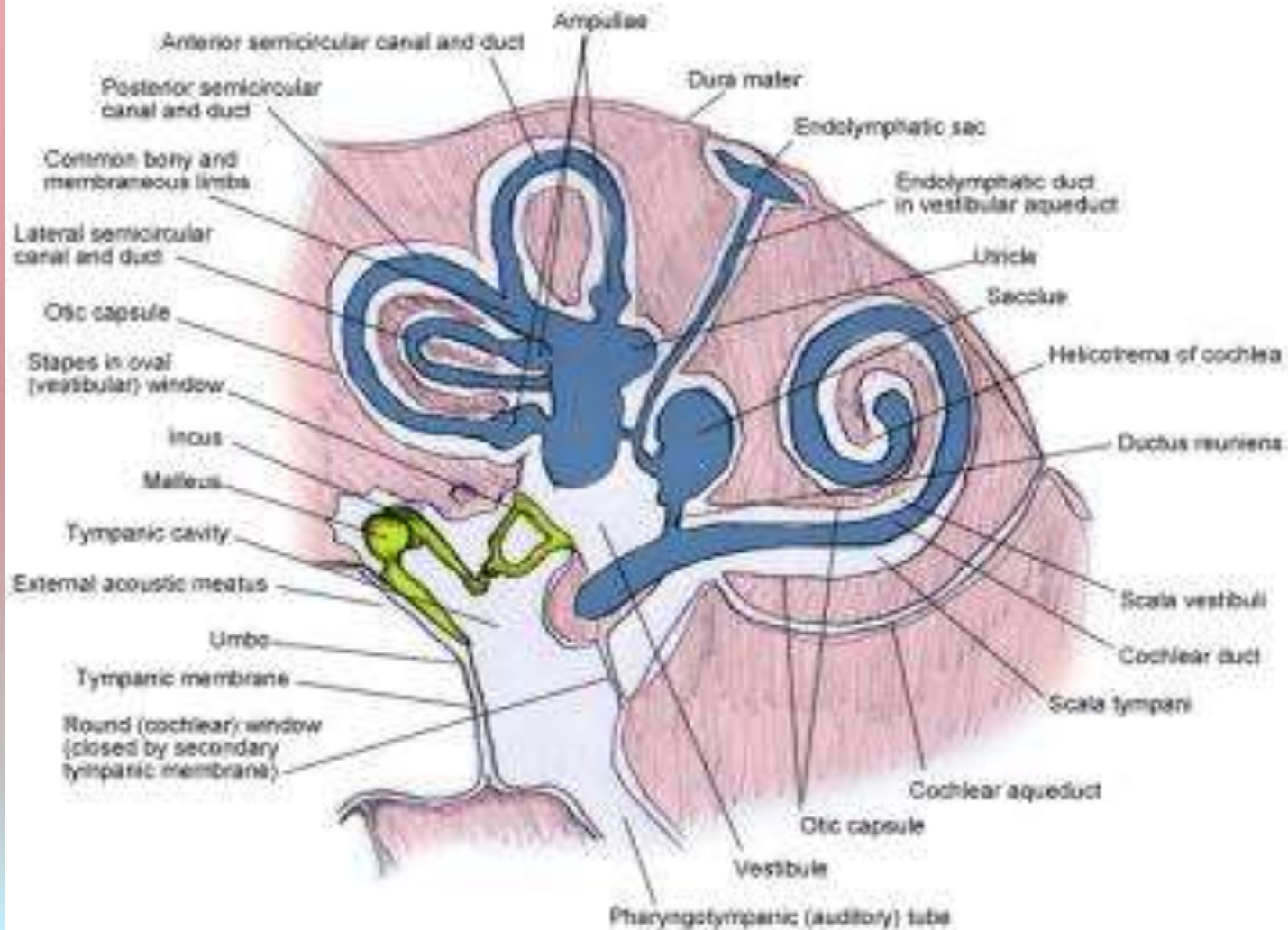
College of Veterinary Medicine

Department of Anatomy



College of Veterinary Medicine

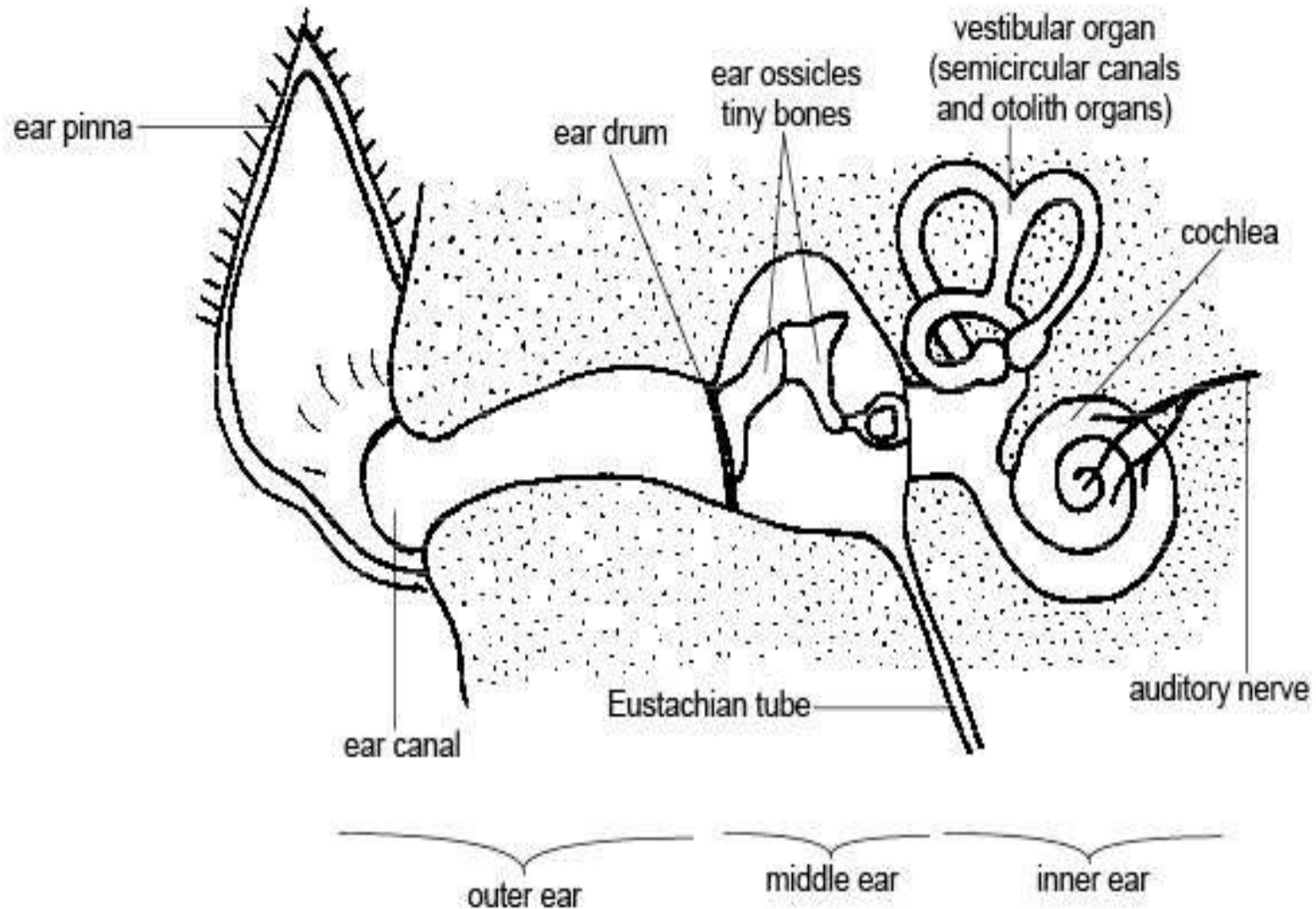
Department of Anatomy





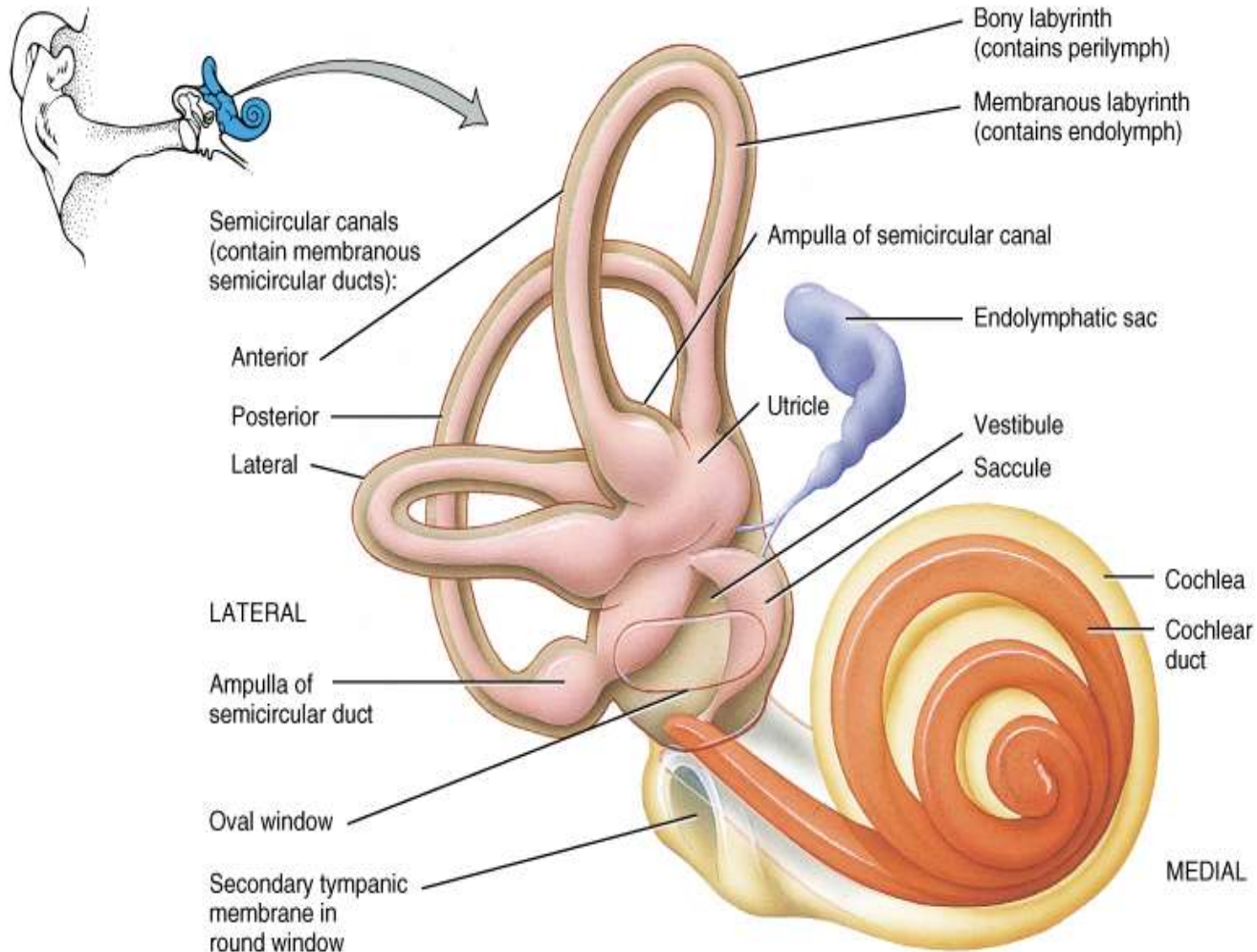
College of Veterinary Medicine

Department of Anatomy



College of Veterinary Medicine

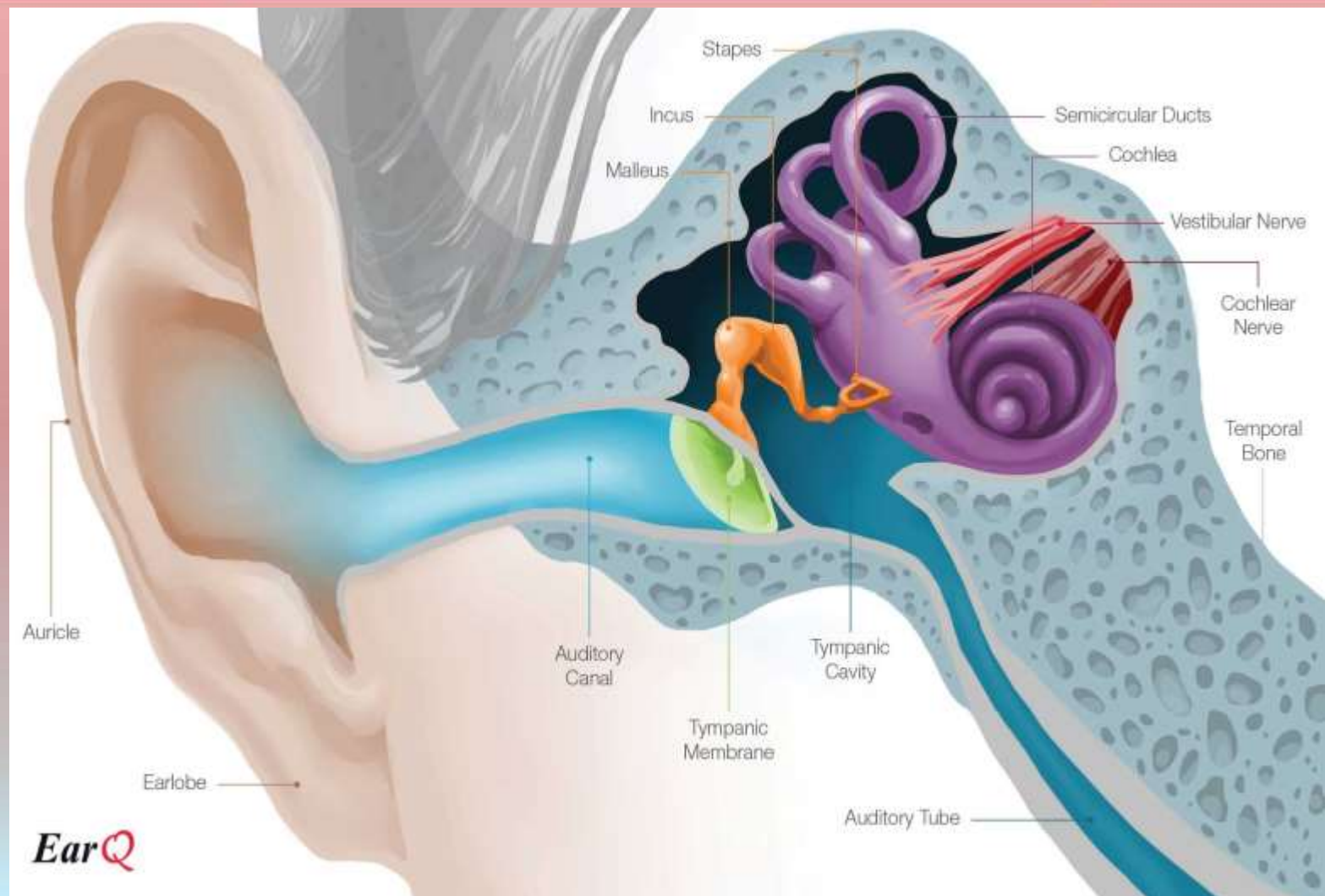
Department of Anatomy





College of Veterinary Medicine

Department of Anatomy

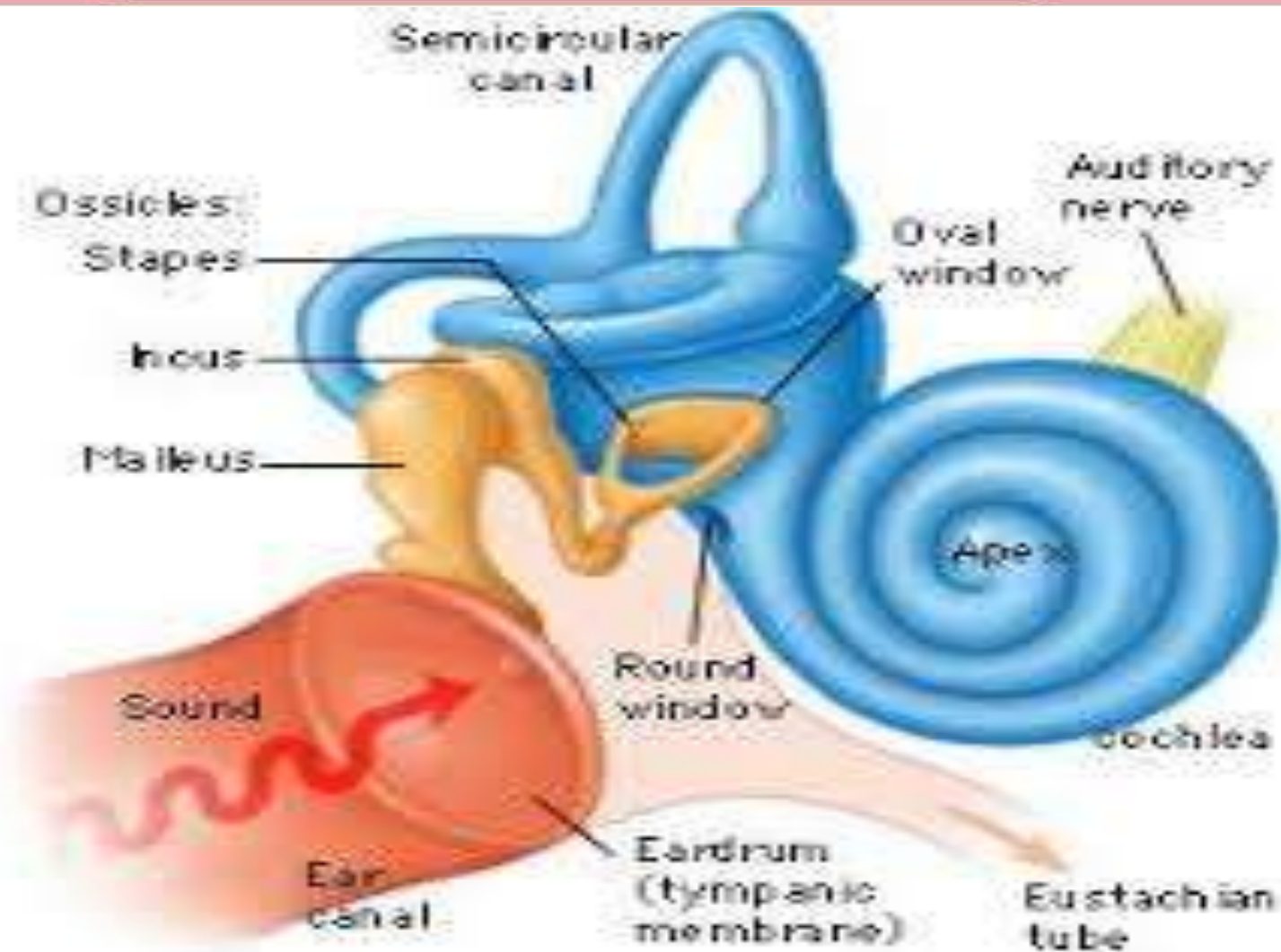


EarQ



College of Veterinary Medicine

Department of Anatomy



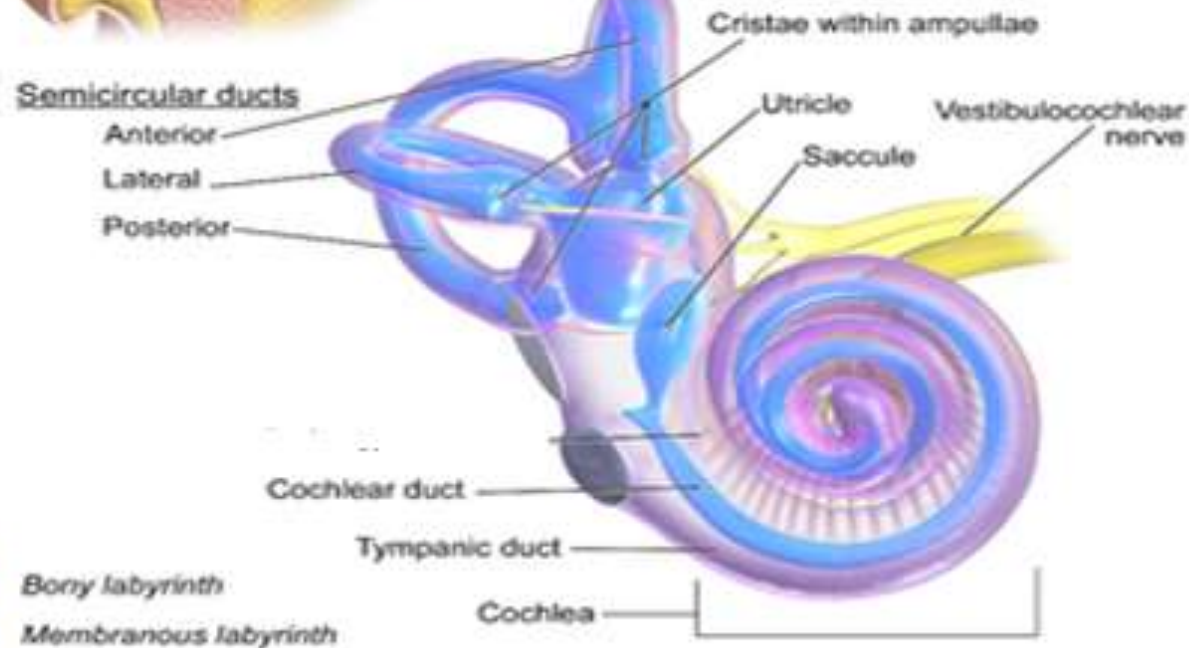
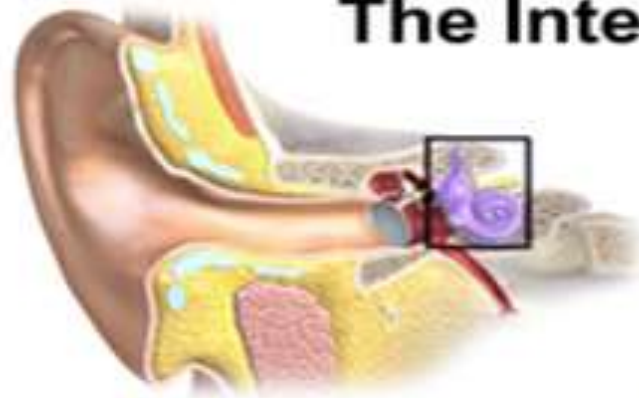

College of Veterinary Medicine

Department of Anatomy



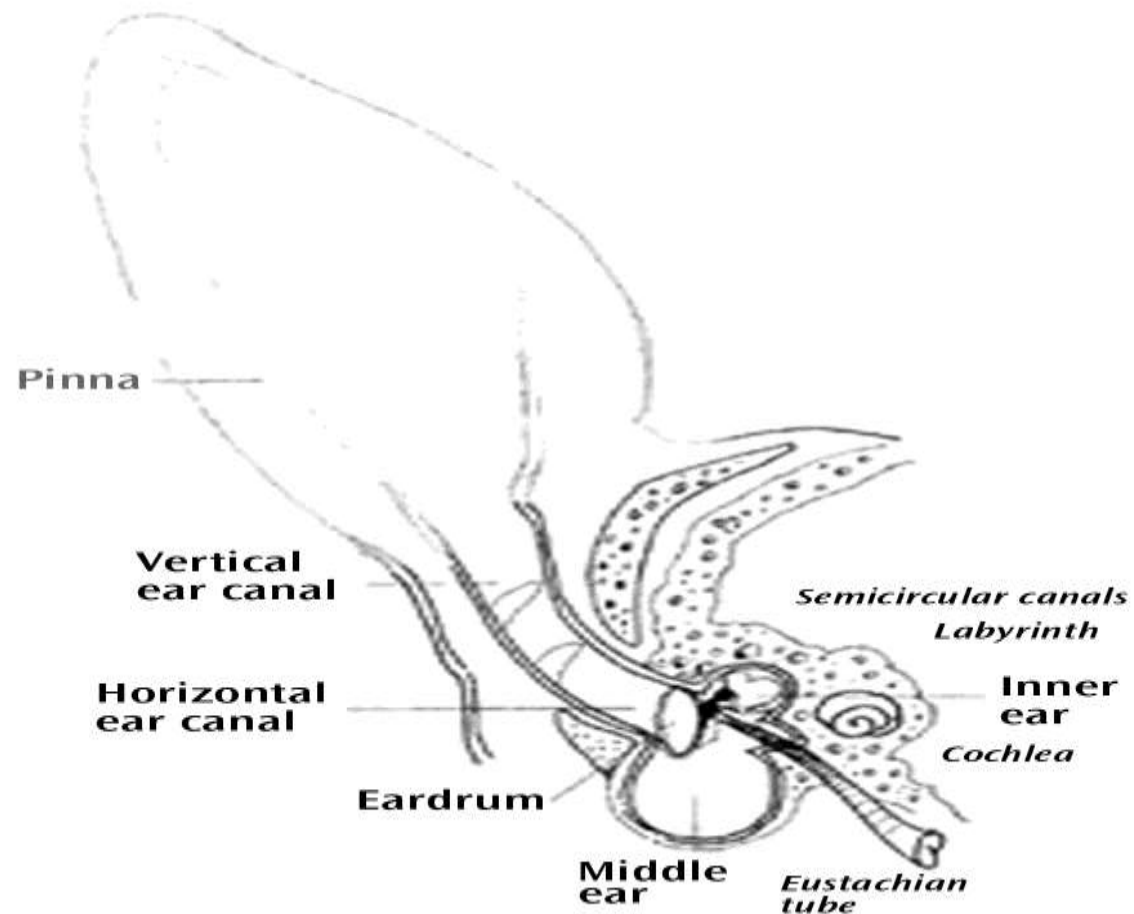
The Internal Ear





College of Veterinary Medicine

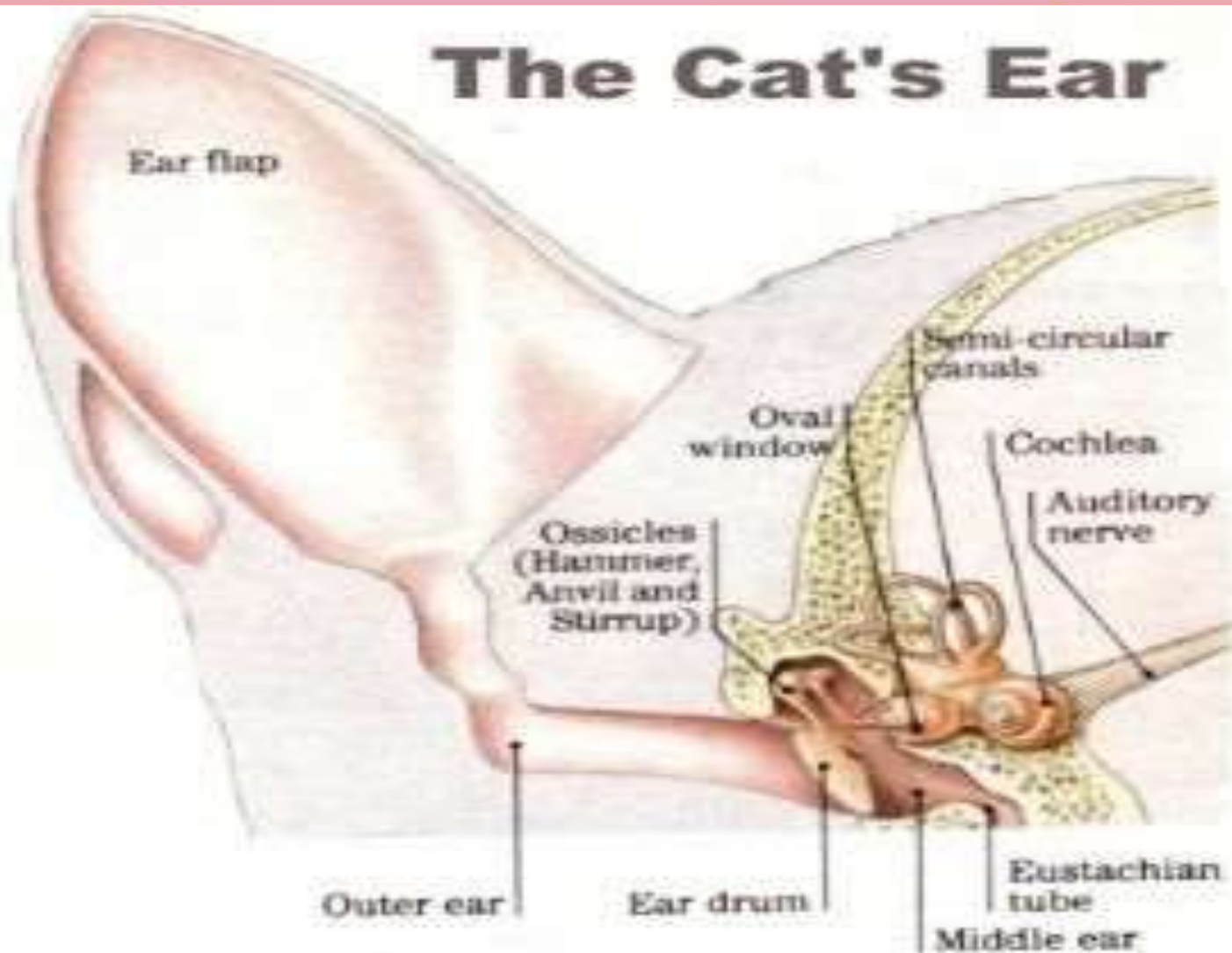
Department of Anatomy





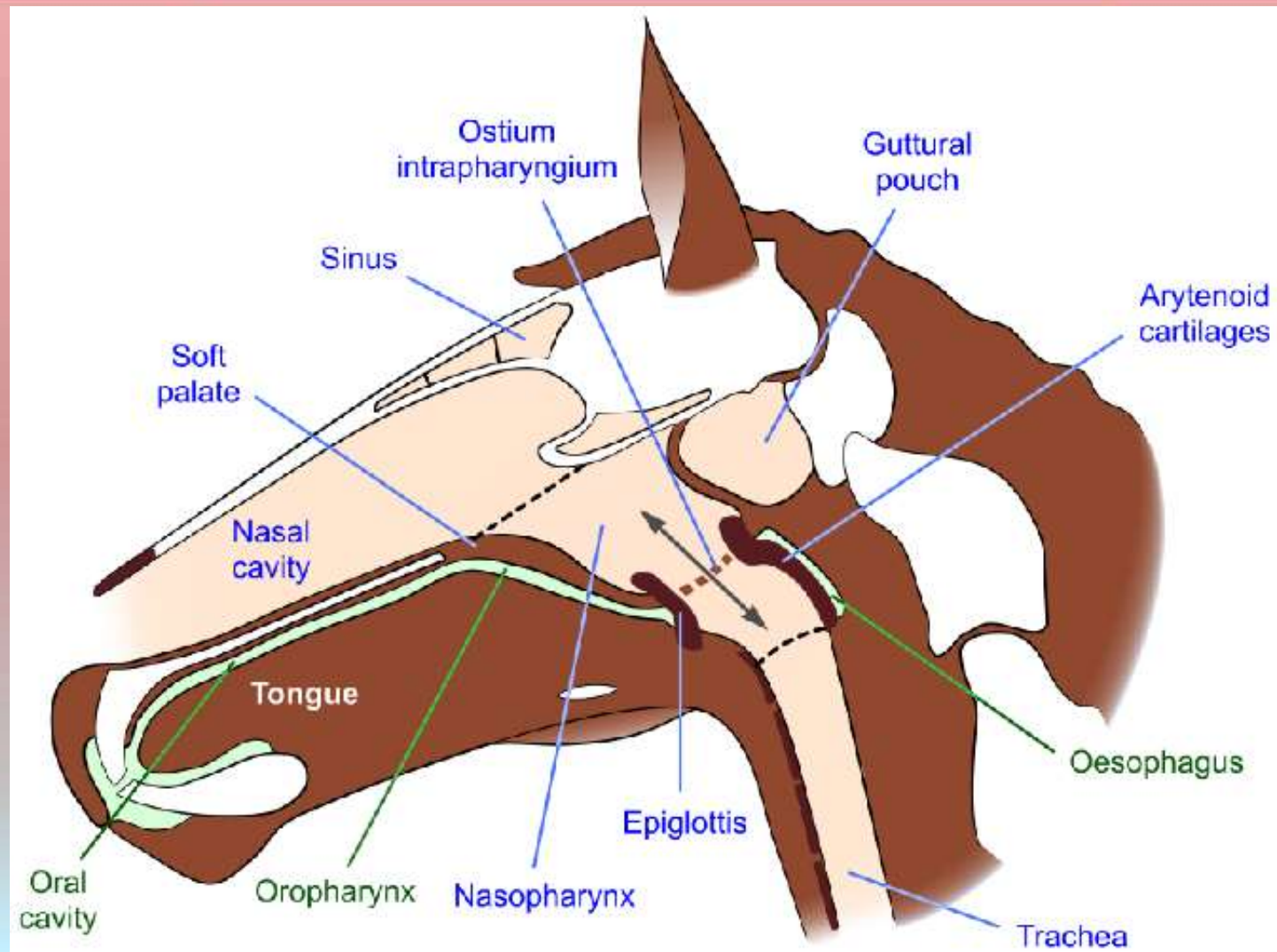
College of Veterinary Medicine

Department of Anatomy





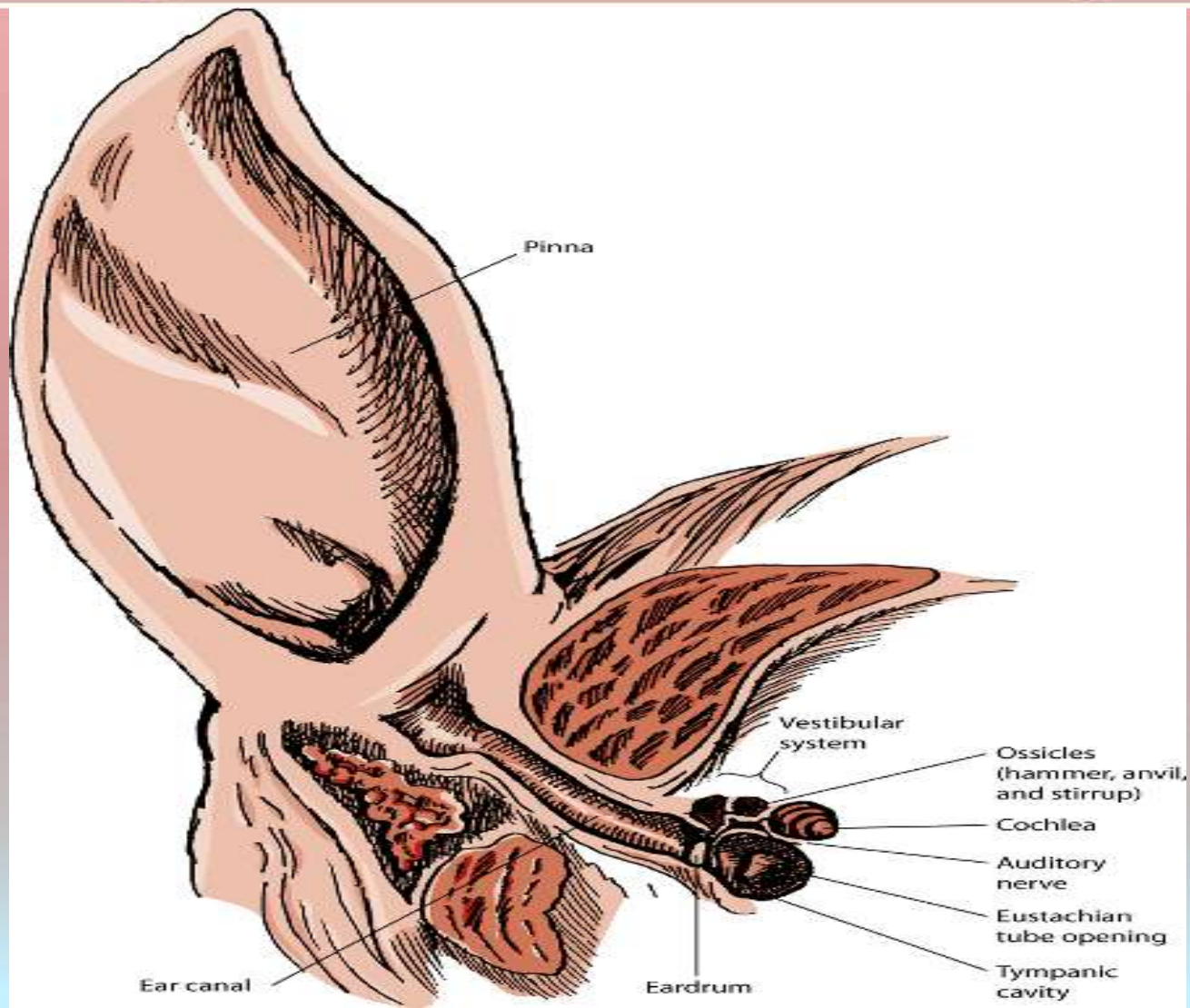
College of Veterinary Medicine Department of Anatomy





College of Veterinary Medicine

Department of Anatomy





College of Veterinary Medicine

Department of Anatomy

